

Are there special needs in correction of transverse deficiency in case of patients with cleft lip and palate?

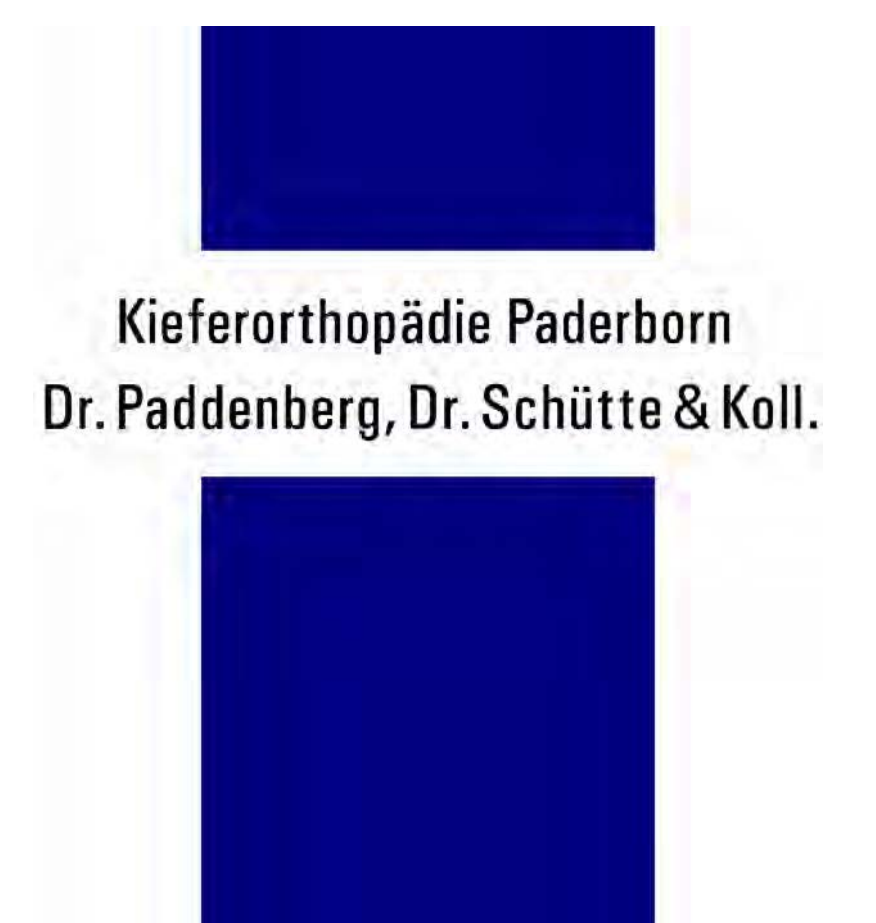
-Case report-

D. Paddenberg, B. Paddenberg, T. Schütte, Ch. Fode

Private office, Paderborn, Germany

91st Congress of the European Orthodontic Society

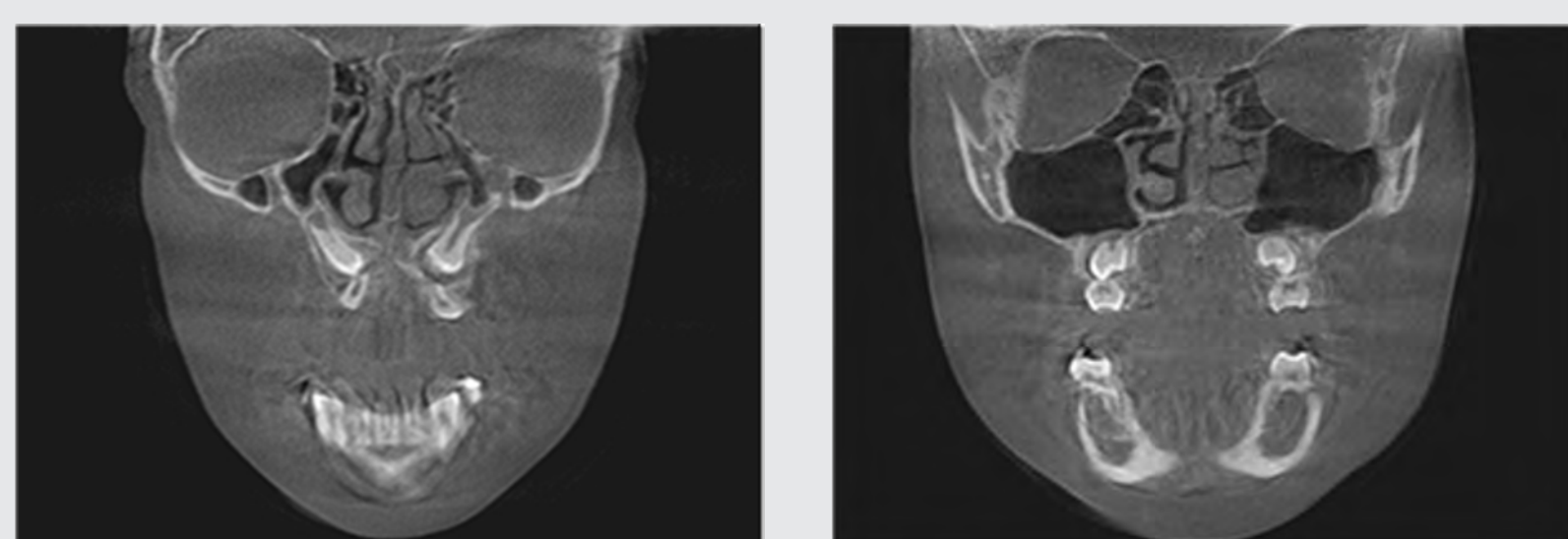
Venice, Italy, June 2015



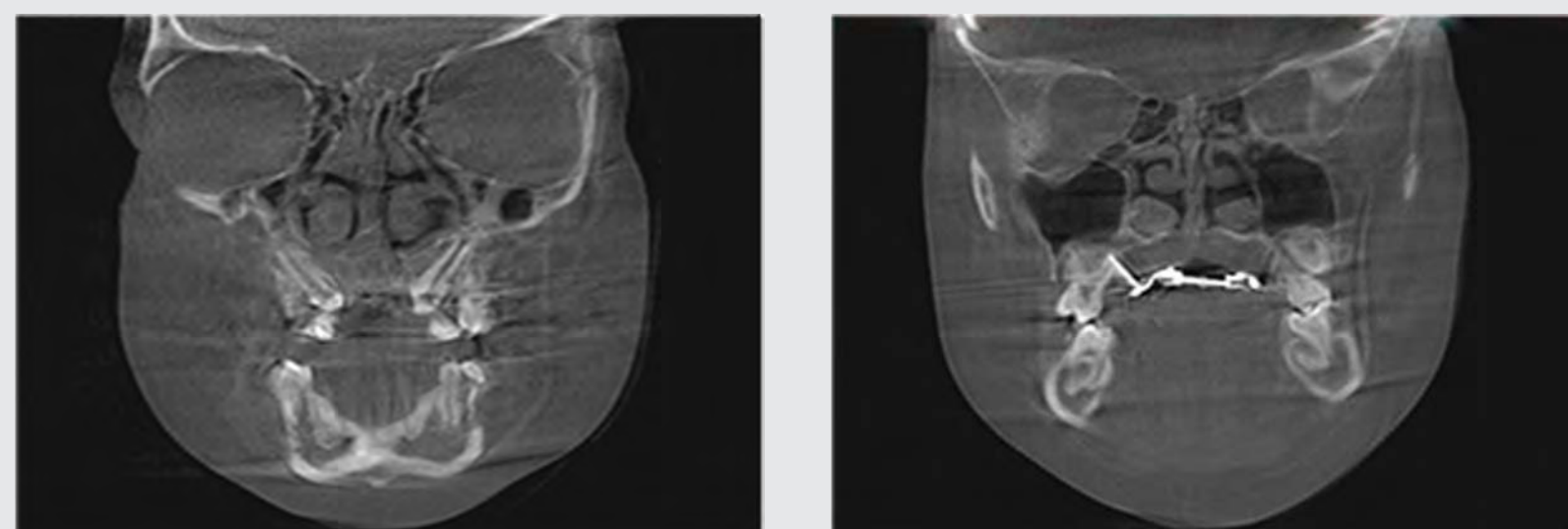
The comprehensive treatment of a patient with (bi-) lateral cleft lip and palate requires an interdisciplinary approach for functionally and aesthetically pleasing results.

Aim

This case report describes the postsurgical orthodontic treatment after transpalatal distraction, which has resulted in overcorrection and severe rotation of both lateral segments.

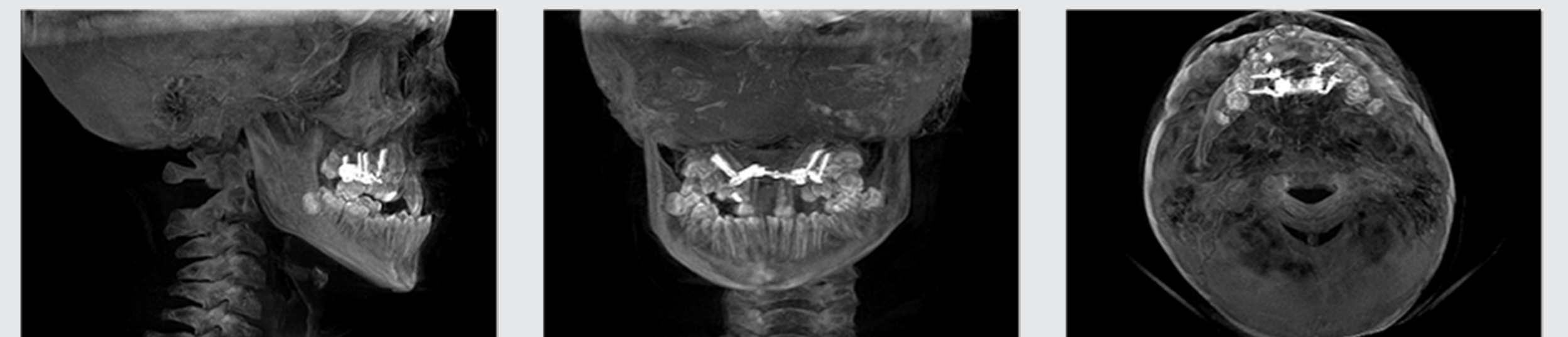


before SARPE
6th April 2010



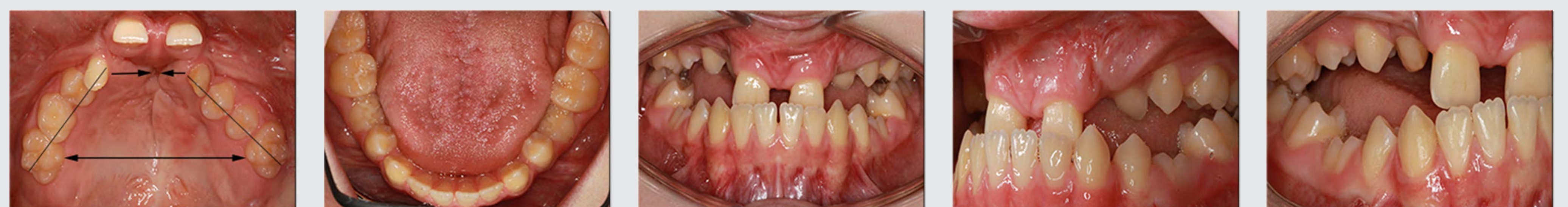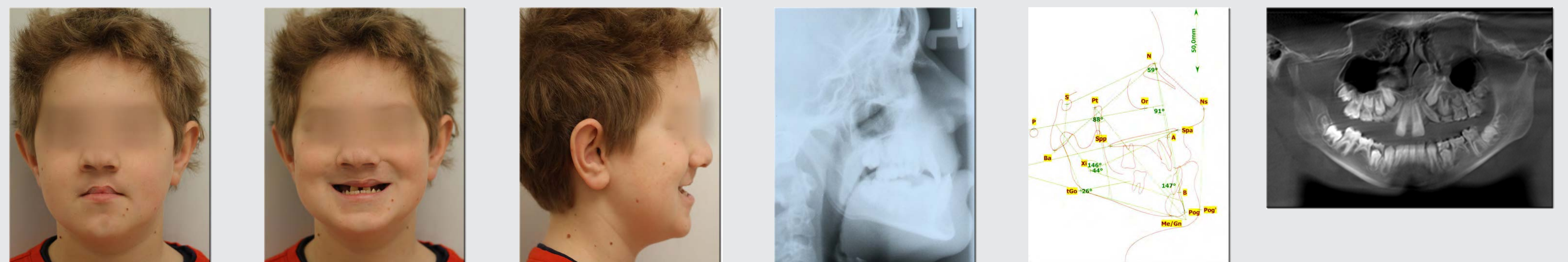after SARPE
8th October 2012

TPD in situ



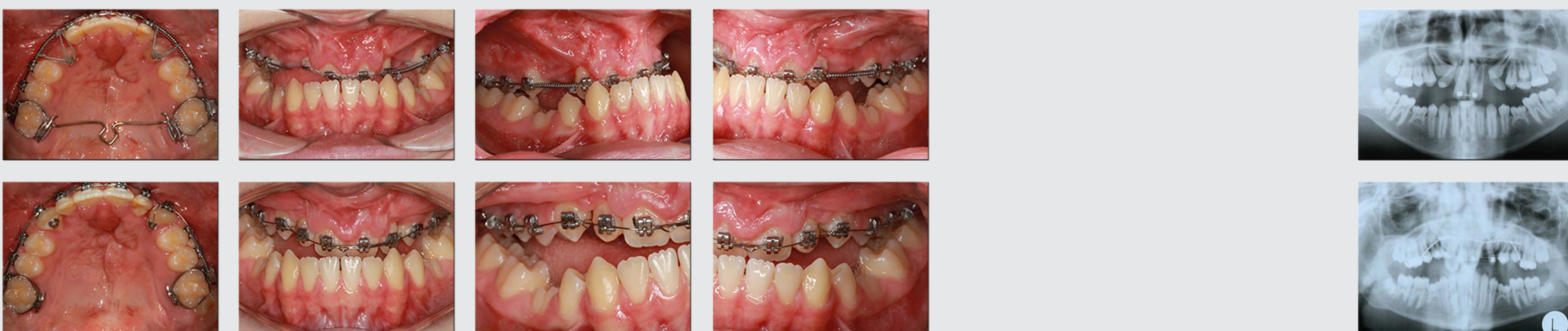Initial situation after referral

- boy, age 12 years and 5 months
- bilateral cleft lip and palate
- condition after surgically assisted rapid palatal expansion (SARPE)
- expansion device TPD (transpalatal distractor according to Umstadt) was removed
- alveolar cleft bone graft was carried out
- Class III skeletal relationship
- severe midface hypoplasia
- displaced upper canines
- agenesis of lower second bicuspids
- rotation of both lateral segments of the upper jaw
- rotation of upper first molars
- posterior over-expansion and anterior compression of the upper jaw



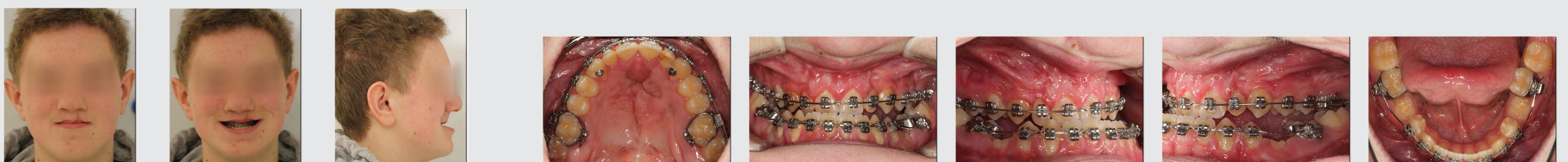
Orthodontic Treatment

- edgewise appliance to align and level upper and lower dental arch, especially by using segmental archwires and flexible transpalatal arches



Results

The correction of the upper dental arch was accomplished through the rotation of both lateral segments with anterior expansion and moderate posterior compression. Moreover, alignment of the teeth, particularly the teeth adjacent to the region of cleft augmentation and the palatally displaced canines was achieved. These are, among other factors, important requirements for the approaching surgical correction of the class III.



Conclusion

Patients with (bi-) lateral cleft lip and palate & transverse maxillary deficiency are often being treated with bone-supported transpalatal distraction, what can lead to rotation of the lateral segments. This can be corrected with modified and individually adjusted orthodontic mechanics. On the basis of sufficient alveolar bone graft alignment of lateral incisors and displaced canines is promising without major complications. Orthognathic surgery to bring the deficient maxilla forward will be necessary to correct the malocclusion. To prevent the risk of sleep apnoea surgical mandibular setback should be avoided.